

Estimating the tumor-breast volume ratio from mammograms

J. Rodríguez^{*}
jrodrigu@uc.edu.ve

P. Linares^{*}
plinares@uc.edu.ve

E. Urrea^{*}
eduardourra@hotmail.com

D. Laya^{*}
danylaya@hotmail.com

F. Saldivia^{*}
felipesaldivia@cantv.net

A. Reigosa[♦]
areigosa@uc.edu.ve

^{*}CEMVICC – Faculty of Science and Technology, University of Carabobo, Valencia, Venezuela

^{*}Breast Pathology Service, Institute of Oncology Dr. Miguel Pérez Carreño, Valencia, Venezuela.

[♦]CIMBUCC – Faculty of Health Sciences, University of Carabobo, Valencia, Venezuela

ABSTRACT

Each year, 182,000 women are diagnosed with breast cancer and 43,300 die, only in America. Currently, more than a million of new cases will be detected around the world. One woman in eight either has or will develop breast cancer in her lifetime. Mammograms are among the best early detection methods. Most women with breast cancer have some type of surgery: Lumpectomy removes only the breast lump and a surrounding margin of normal tissue. Partial or segmental mastectomy or quadrantectomy removes more breast tissue than a lumpectomy (up to one-quarter of the breast). In a total mastectomy the surgeon removes the entire breast, including the nipple. This operation is sometimes used to treat stage 0 breast cancers. For most women with stage I or II breast cancer, breast conservation therapy (lumpectomy and radiation therapy) is as effective as mastectomy. Survival rates of women treated with these 2 approaches are the same. However, breast conservation therapy is not an option for all women with breast cancer. One of the main factors to decide which type of surgery must be used (lumpectomy, quadrantectomy or total mastectomy) is the tumor-breast volume ratio. Unfortunately, because the mammograms are two-dimensional projections of the breast, a process to measure this relationship with the needed accuracy does not exist. So, a correct decision depends on the specialist's ability to imagine the 3D reconstruction from the mammograms. In order to assist the decision making of the surgeon, in this work we have implemented a software application which allows the surgeon to input the mammograms of the patient and obtain a 3D representation of the breast and the tumor. In summary, the software groups a set of tools to segment the breast and tumor from the input mammograms in an interactive way using the intelligent scissors technique, visualize the mammograms in 3D, reconstruct the 3D representation of the breast and tumor and compute a value which represents the volumetric ratio between the breast's reconstruction and the bounding volume of the tumor. This value can be used as a less subjective indicator to decide whether a lumpectomy or quadrantectomy is advisable.

Keywords

Breast-Conserving Surgery, Surface Reconstruction, Scientific Visualization .

1. INTRODUCTION

Breast Cancer has become a public health problem during the last 50 years. Currently, more than a

million new cases of breast cancer are diagnosed [Par05]. There are numerous breast pathologies, from those that do not involve a surgical intervention to the pathologies that require complex treatments that may include the total extirpation or partial section of the mamma. In this work, interest is focused in the cases where the diagnostic suggests a surgical action and the decision to be taken is whether to carry out a total or partial mastectomy. A main factor to be taken into account by the specialist, to decide what kind of procedure to follow, is based on the appraisal of the volumetric proportion between the tumor and the whole breast. This

Permission to make digital or hard copies of all or part of this work for personal or classroom use is granted without fee provided that copies are not made or distributed for profit or commercial advantage and that copies bear this notice and the full citation on the first page. To copy otherwise, or republish, to post on servers or to redistribute to lists, requires prior specific permission and/or a fee.

Copyright UNION Agency – Science Press, Plzen, Czech Republic.

proportion is estimated from the patient mammograms, using X-ray projections in two or three orientations, namely, craniocaudal, lateral and medio-lateral oblique [Kop98], and also from the clinician palpation. An acceptable judgment by the specialist demands a broad experience and a special competence to mentally reconstruct the volume from the projection two-dimensional information. In fact, different judgments from different specialists for the same patient occurs frequently. In this work, the design and development of a software application to produce and visualize a volumetric approximation of the breast and the tumor is undertaken. It is also intended to produce a numeric indicator associated to the volume ratio between the tumor and the breast regions so that the specialist can have more objective information when deciding the kind of surgical intervention to be carried out. The software system should be interactive and make use of two digitized mammographic views.

2. RELATED WORK

Breast-conserving surgery (BCS), one of the most important innovations in the treatment of breast cancer, started in 1972 as a proposal of Veronesi et al. [Ver77] at the National Cancer Institute of Milan, Italy. Patients were selected for quadrantectomy if breast tumors had a largest diameter of 2 cm or less on physical examination and no palpable axillary nodes [Ver02]. Similarly, Fisher et al. [Fis02] have been working in comparisons with lumpectomy taking into account for selection of patients women with invasive breast tumors that were 4 cm or less in their maximal diameter. Retrospective studies have shown that breast-conserving treatment and mastectomy are equivalent if patients are selected appropriately [Ver02][Fis02]. Contraindications may arise from several factors such as pregnancy, number and location of malignancies, patient medical history, and the size of the tumor in relation to the size of the breast [Win92].

Several works have been previously published in relation to breast cancer and computational applications in order to assist the specialists in the diagnosis and surgical planning. Zwiggelaar et al. [Zwi04] and Petroudi et al. [Pet03] have worked on mammograms in order to detect some structures which can be interpreted as indicators of breast cancer risk. In a technique for both the detection and anatomical classification of linear structures in mammographic images, based on the statistical modelling of scale-orientation signatures, was developed. In [Pet03] an objective quantitative

measure of breast density was proposed based on a new approach to breast parenchymal pattern classification. In order to obtain a good segmentation of the breast from mammograms, Wirth et al. [Wir05] has developed a new algorithm for breast region segmentation using fuzzy reasoning. The algorithm uses morphological pre-processing to suppress artifacts and accentuate the breast region, followed by a fuzzy rule-based algorithm to classify the breast tissue region. Although this technique produces nice results to segment the breast from mammograms, the results for the tumor segmentation is not accurate. Finally, in volume reconstruction of the breast, there are very interesting results with Magnetic Resonance Imaging (MRI)[Cot05][Car04][Sub04], but little work has been done from X-ray mammography. This is true despite X-Ray mammography is the standard in clinical practice and the most widely used method for early detection of breast cancer. Carotenuto et al. [Car04], Subramanian et al. [Sub04] and Coto et al. [Cot05] propose software tools to explore, identify, process, visualize and quantify lesions from breast dynamic contrast enhanced MRI data (DCE-MRI). In this paper a volumetric approximation of the breast and the tumor is undertaken from X-ray mammography data and a numeric indicator associated to the volume ratio between the tumor and the breast regions is computed.

3. OVERVIEW OF THE PROPOSAL

The design and development of an application with the aforementioned characteristics involves, on one hand, segmenting both tumor and breast, and on the other, the three-dimensional reconstruction from the segmented images. A third step consists in the computation of the tumor-breast volume ratio numerical indicator using the reconstruction.

The prototype version of the system uses two mammograms in the craniocaudal and lateral views and offers the specialist the chance to identify the breast and the tumor regions by drawing, with the mouse, directly over the images. The drawing of both regions is in reality assisted by the software by means of the use of a contour detection strategy known as Intelligent Scissors [Mor95]. This technique for contour detection avoids an unwanted divergence from the targeted contour. This divergence could arise from the lack of drawing skills of the user. Once the tumor and breast are segmented in the mammography images, both images and contours are mapped into two planes in the space. These two planes can be displaced horizontally and vertically by the specialist until a location, coherent one in relation to the other, is

reached. Starting with this information, the system performs a volumetric reconstruction of the breast and tumor's bounding volume using a strategy based on contour connection [Scu89] and producing a 3D visual model of it. Additionally, the tumor-breast volume ratio is computed based on the volume reconstruction of the breast and the bounding volume of the tumor. This ratio is presented to the specialist as a numerical indicator. The system was developed using a software interactive tool implemented on the Java language and 3D graphic libraries for Java based on the standard OpenGL (Jogl) that can be run on a conventional personal computer.

4. SEGMENTATION

As mentioned in the previous section, the first step in the process of reconstruction and volume estimation consists in identifying the regions corresponding to the tumor and breast in the input mammograms. After testing some segmentation schemes based on filters [Mar98] and active contours [Kas87][Dan93] with poor results, especially in the segmentation of the tumor, it was decided to implement a semi-automatic strategy allowing the specialist interaction. This strategy permitted to add expertise to the recognition process. In that sense, an interactive contour detection strategy known as Intelligent Scissors [Mor95] was adopted. This approach is considered to be in the middle between the fully automatic and the fully manual techniques that aim at contour detection. Intelligent Scissors permit the user to draw up quickly and accurately the boundaries of regions in digital images by simple movements of the mouse. When the cursor of the mouse gets close to the border of the object, the curve following the mouse movement adheres to the contour as if it had autonomous behavior (live wire). In this manner, the user does not have to trace an exact curve over the contour of the region of interest, but to drag the live wire close to the border of interest and the curve "will know" how to adhere to the correct border.

The determination of the border using Intelligent Scissors can be formulated as a problem of search in graphs where the goal is finding an optimal path between an initial and a final pixel. That is to say, the image is define as a graph $G=(V, E)$, where V is the set of pixels and E is the set of edges between adjacent pixels in an 8-neighborhood. Each edge has an associated cost which is computed as a local cost function involving three functional components related to the Laplacian, $f_z(q)$, the gradient magnitude, $f_G(q)$, and the gradient direction, $f_D(p,q)$.

The expression for the local cost function, $l(p,q)$ from pixel p to its neighbor q (within an 8-neighborhood), is given as follows:

$$L(p,q)=w_z \cdot f_z(q) + w_G \cdot f_G(q) + w_D \cdot f_D(p,q) \quad (1)$$

Where, w_z , w_G and w_D are the weights associated to the corresponding characteristic function. The optimal cost is given by the minimum accumulated cost that results from adding the local costs in a path from the initial to the end pixel.

5. 3D RECONSTRUCTION

The 3D reconstruction of the tumor and breast from the mammographic views follows an ad hoc process that consists of two stages: matching and reconstruction.

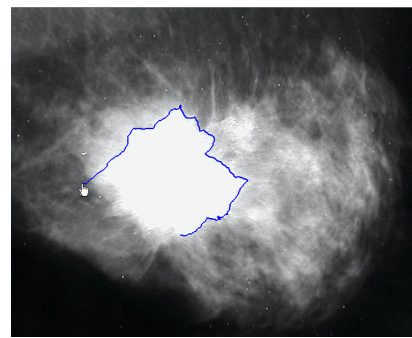


Figure 1. A "Live wire" contour is drawn by means of the intelligent scissors tool.

Once the tumor and breast contours are delimited in both input mammograms they are mapped into two planes that are orthogonal between them in the manner the input mammograms were acquired from the patient (craniocaudal and lateral projections). From this moment onwards, the matching stage takes place. In this stage the projected planes containing the mammograms are displaced horizontally and vertically until they reach a matching position according to the specialist judgment. Once the matching is achieved, there will be two curves in the space, associated to the contours of the mamma, and two closed contours related to the tumor. One of these curves, and its corresponding closed contour, will be placed over the XZ plane and the other over the YZ plane. An illustration of the appearance of curves and contours is shown in figure 2.

From the projected curves in spatial matching located over the XZ and YZ planes, it is possible to estimate an approximation of the original volume associated to these projections. It was decided to approximate the exterior surface of the breast assuming a semi-elliptic shape in sections of the surface parallel to its base.

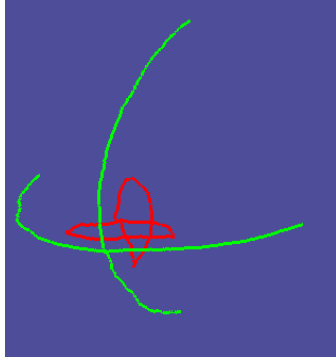


Figure 2. Result of the Matching Stage

The axes of the ellipsoidal base were determined by the projections of the curves over the XY plane, such as shown in figure 3.

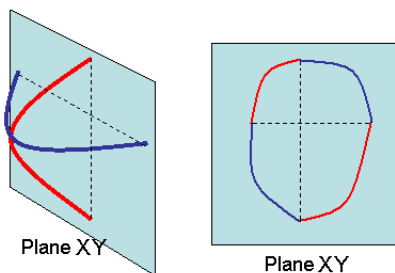


Figure 3. Construction of the semi-ellipsoidal base of the mamma

It can be noticed that the system of axes obtained by projecting the curves over the XY plane is not symmetrical therefore the semi-ellipsoidal shape is a composition of four sections of ellipses, each one of them corresponding to one quadrant.

Following the outlining of the base, the projection XY plane is moved along the positive Z axis in order to get new sets of axes and semi-ellipses that approximate the peripheral surface of the mamma. The parallel semi-ellipses are shown in figure 4.




Figure 4. 3D reconstruction of contours on the surface of the mamma.

Once the contours are generated, a basic algorithm for contours connection [Scu89] is executed in order to produce a triangular mesh representing the approximate surface of the breast.

The representation of the tumor is approached in a different manner because tumors can occur in a multiplicity of shapes so that defining a pattern from the 2D projections is not trivial. In this work, as a first approximation, it was decided to represent the tumor by a bounding volume. With this approximation, given that the tumor is always enclosed by its bounding volume, the estimated tumor-breast volume ratio will be over the real ratio. The consequences of this coarse estimation have to be assessed before this indicator is applied in the decision making process. Different bounding volumes (box, sphere and ellipsoid) will be available for the specialist to select the most suitable for the tumor. Figure 5 shows the triangular surface of the breast obtained from the previous semi-ellipses by a connecting contour algorithm. The bounding box of the segmented tumor is also presented in the figure.

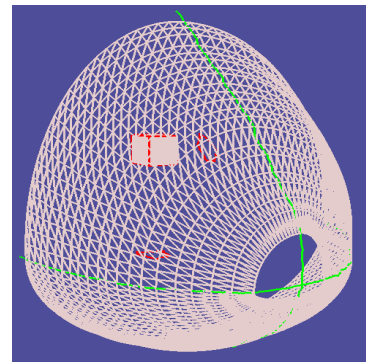


Figure 5. 3D reconstruction of the breast's surface and bounding box of the tumor

6. RESULTS

So far partial results have been obtained from the development and use of the application. It is still pending an exhaustive validation process to be carried out by the specialists. As mentioned before, the software tool was developed on Java language using Java libraries for 3D graphics based on the standard OpenGL (Jogl). The intention for this selection was to have the possibility of using it on a typical personal computer configuration. No special features in terms of graphic hardware are needed. Consistently with the process described above, the software application consists of three stages, namely, segmentation, spatial correspondence and 3D reconstruction. In the segmentation stage the breast border and the tumor closed region are interactively delimited. The spatial matching stage allows the convenient positioning of the planes. The 3D reconstruction deals with the building of a triangular

mesh from the semi-elliptical approximations of the breast surface and the determination of a bounding volume for the tumor. For each selected bounding volume a tumor-breast ratio approximation showing the numerical index on the screen.

The general appearance of the application is shown in the following figures. In summary, two areas can be distinguished, the biggest is the display area located at the left of the screen and the control area located at the right. In the display area three tags can be distinguished. The first and second tags correspond to the loading and segmentation processes for both craniocaudal and lateral mammograms (figure 6).

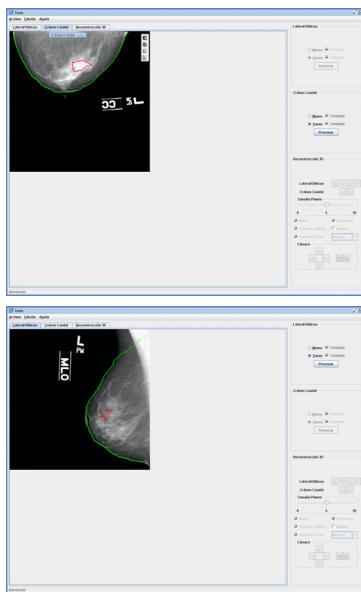


Figure 6. Craniocaudal and lateral views on the display area.

Finally, the third tag is associated to the spatial matching and 3D reconstruction of the breast and tumor (figure 7).

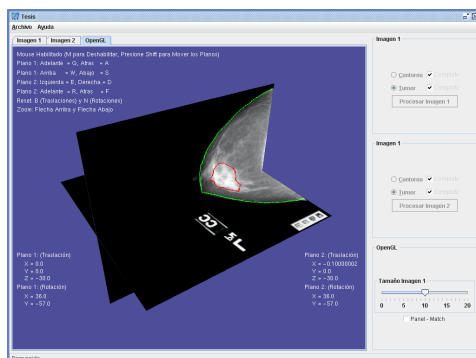


Figure 7. Spatial matching and 3D reconstruction screen.

The mammograms in spatial matching, together with the contours obtained in the segmentation stage and mapped over the images, can be seen in the central display area.

A rear view of the reconstruction of a breast based on the information available in the input mammograms as well as the bounding box of the tumor is presented in figure 8.

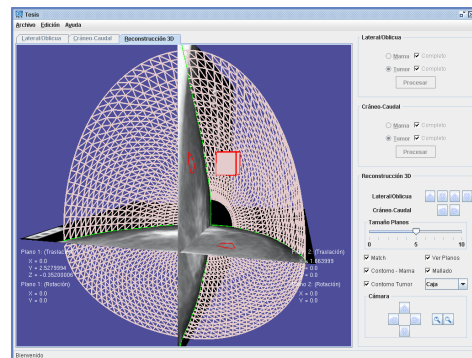


Figure 8. 3D reconstruction of the breast.

Accordingly, in figure 9, a frontal view of the same reconstruction without the mammograms, so that the interest volumes are more easily distinguished, is presented.

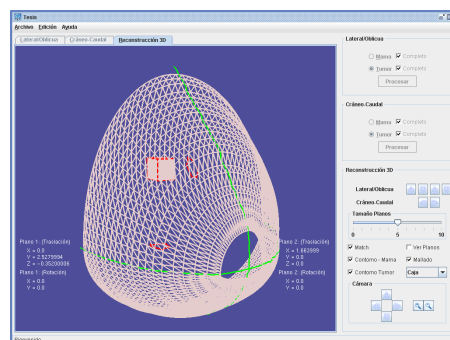


Figure 9. 3D reconstruction of the breast hiding the mammograms

7. CONCLUSIONS

A software application intended to be used as a decision support tool for the study of the tumor-proportion from standard mammograms (craniocaudal and lateral) has been presented. The current state of development allows the specialist to delimit interactively the contours of breast and tumor within the input mammograms and establish the spatial matching between mammographic views. The software uses this segmentation and matching to carry out a 3D reconstruction of the breast and determine automatically the bounding volume of the tumor and compute a numerical indicator of the tumor-breast volume ratio between the bounding volume of the tumor and the reconstruction of the breast. This computation may prove to be of

significant value for the decision making and surgical planning. Clinical validation of the results is still pending. Accordingly, the volumetric approximation of the breast does not take into account the anatomical information available in the medio-lateral oblique mammogram which is important to incorporate the part of the breast starting in the armpit. Future developments of the application should incorporate this information.

8. ACKNOWLEDGMENTS

This work is part of the project "Building a visualization room", No. 2005-12 granted by the CDCH-UC.

9. REFERENCES

- [Car04] Carotenuto, L., Ercolani, M., Passariello, R., et al. Software tool for computer aided diagnosis of breast cancer in contrast enhanced MR sequences. In EuroPACS-MIR 2004 in the Enlarged Europe, pages 361-364, 2004.
- [Cot05] Coto, E., Grimm, S., Bruckner, S., et al. MammoExplorer: An Advanced CAD Application for Breast DCE-MRI. In VMV'2005 Proceedings, 2005
- [Dan93] Daneels, D., Campenhout, D., Niblack, W. et al. Interactive Outlining. An improved approach using active contours, SPIE Proceedings of storage and retrieval for image and video databases, vol.1908, pp.226-233, 1993.
- [Fis02] Fisher, B., Anderson, S., Bryant, J., et al. Twenty-Year Follow-up of a Randomized Trial Comparing Total Mastectomy, Lumpectomy, and Lumpectomy plus Irradiation for the Treatment of Invasive Breast Cancer. *N Engl J Med* 2002 347: 1233-1241
- [Kas87] Kass, M., Witkin, A., Terzopoulos D.. Snakes: Active contour models, Proc. Of the First international Conference on Computer Vision, London, England, pp.259-268, 1987.
- [Kop98] Kopans, D. B., Breast Imaging, 2nd Edition, Philadelphia, Lippincott-Raven Publishers, 1998.
- [Mar80] Marr, D., Hildreth, E., A theory of edge detection, Proceedings of the Royal Society of London-Series B: Biological Sciences, vol.207, No.1167, pp 187-217, 1980.
- [Mor95] Mortensen, E., Barreto, W.. Intelligent Scissors. *Computer Graphics (SIGGRAPH '95)*, pp. 191--198 (1995).
- [Par05] Parkin, D. M., Bray, F., Ferlay, J., Pisani, P. Global Cancer Statistics 2002. *CA Cancer J Clin* 2005 55: 74-108
- [Pet03] Petroudi, S., Kadir, T., Brady, M. Automatic classification of mammographic parenchymal patterns: a statistical approach. Proc. of the 25th Annual International Conference of the IEEE, pages 798- 801, 2003.
- [Scu89] Scumaker, L. Reconstructing objects from cross-sections. *Computation of curves and surfaces*. Kluwer Academics, pages 275–309, 1989.
- [Sub04] Subramanian, K., Brockway, J., and Carruthers, W. Interactive detection and visualization of breast lesions from dynamic contrast enhanced MRI volumes. *Computerized Medical Imaging and Graphics*, 28(8):435-444, 2004.
- [Ver77] Veronesi, U., Banfi, A., Saccozzi, R., et al. Conservative treatment of breast cancer: a trial in progress at the Cancer Institute in Milan. *Cancer* 1977;39:Suppl:2822-2826.
- [Ver02] Veronesi, U., Cascinelli, N., Mariani, L., et al. Twenty-year follow-up of a randomized study comparing breast-conserving surgery with radical (Halsted) mastectomy for early breast cancer. *N Engl J Med* 2002;347:1227-1232.
- [Win92] Winchester, D. P., Cox, J. D. Standards for breast-conservation treatment. *CA Cancer J Clin* 1992 42: 134-162
- [Wir05] Wirth, M., Nikitenko, D., Lyon, J. Segmentation of the Breast Region in Mammograms using a Rule-Based Fuzzy Reasoning Algorithm. *ICGST International Journal on Graphics, Vision and Image Processing*, vol.05 (2), pages 45-54, 2005.
- [Zwi04] Zwiggelaar, R., Astley, S.M., Boggis, C. Taylor, C. Linear structures in mammographic images: detection and classification. *Medical Imaging, IEEE Transactions on Publication*. Vol. 23(9), pages: 1077-1086, 2004.